

EUROPEAN JOURNAL OF ONCOLOGY


GIORNALE EUROPEO DI ONCOLOGIA

Official Organ of the
Italian Society of Tumours
SIT

Prevention, Diagnosis, Therapy

*Organo Ufficiale della
Società Italiana Tumori
SIT*

Prevenzione, Diagnosi, Terapia



Institute Ramazzini / *Istituto Ramazzini*

*The European Journal of Oncology is indexed by Excerpta Medica (EMBASE), the Elsevier BioBASE, Science Citation Index Expanded (SciSearch®) and Journal Citation Report/Science Edition
Il Giornale Europeo di Oncologia è recensito su Excerpta Medica (EMBASE), Elsevier BioBASE, Science Citation Index Expanded (SciSearch®) e Journal Citation Report/Science Edition*

Mattioli  1885

Aloe arborescens preparation and liver health

Preparazione a base di Aloe arborescens e salute del fegato

Wagida A. Anwar*, Pirkka V. Kirjavainen**, Jaana Isola**, Mohamed El Zarka***, Tony Moros Spiros***, Hani El-Nezami**

* Ain Shams University, Faculty of Medicine, Cairo, Egypt

** University of Kuopio, School of Public Health and Clinical Nutrition, Kuopio, Finland

*** Spiros Foundation, Egypt

Summary

Aloe arborescens Miller var. *natalensis* Berger (so called as “ALOE”) is traditionally valued herbal medicine for gastrointestinal complaints, skin injuries and burns. The different pharmacological and therapeutic activities of ALOE have been studied. ALOE extracts have been reported to show anti-inflammatory, antidiabetic and antitumorogenic effects. In F344 rats, ALOE has been shown to have beneficial effects against colorectal tumorigenesis and formation of liver preneoplastic lesions. The aim of this study was to evaluate the effects of oral intake of ALOE preparation (*Aloe arborescens*, honey and distillate) on liver health. For this purpose, we investigated the effect of oral ALOE supplementation on the splenic and hepatic cellular immune functions in mice and on dimethylnitrosamine (DMN) – induced liver fibrosis in rats. The studied immune parameters included the presence and cytokine production of different T-cell populations, including T-cell helper (CD4+) subpopulations (Th1, Th2, Th17 and Tregs), cytotoxic T-cells (CD8+) and Natural Killer T (NKT) cells as well as Natural Killer (NK) cells. The anti-fibrogenic potential of ALOE was evaluated based on

Riassunto

Aloe arborescens Miller var. *natalensis* Berger (nota come “ALOE”) è tradizionalmente utilizzata in erboristeria per problemi gastrointestinali, lesioni cutanee e ustioni. Sono state studiate molteplici attività farmacologiche e terapeutiche dell’ALOE. Gli estratti di questa pianta producono effetti anti-infiammatori, antidiabetici e antitumorali. Nei ratti F344, l’ALOE ha dimostrato avere effetti benefici contro la cancerogenesi coloretale e la formazione di lesioni preneoplastiche del fegato. Obiettivo di questo studio era quello di valutare gli effetti della somministrazione orale di una preparazione a base di ALOE (*Aloe arborescens*, miele e distillato) sulla salute del fegato. A questo scopo è stato studiato l’effetto della supplementazione orale di ALOE sulle funzioni immunitarie cellulari epatiche e spleniche nei topi e su dimetilnitrosamina (DMN) – che induce fibrosi epatica nei ratti. I parametri immunitari studiati includevano la presenza e la produzione di citochine di diverse popolazioni di cellule T, comprese le subpopolazioni di cellule T helper (CD4+) (Th1, Th2, Th17 e Tregs), cellule T citotossiche (CD8+) e T Natural Killer (NKT) così come le cellule Natural Killer (NK). Il poten-

Received/Pervenuto 6.4.2009 - Accepted/Accettato 15.6.2009

Address/Indirizzo: Dr. Wagida A. Anwar, Department of Community, Environmental and Occupational Medicine, Faculty of Medicine, Ain Shams University, Abassya, Cairo, Egypt - Tel./Fax +202/24837888 - E-mail: wanwar2@hotmail.com

hepatic stellate cells (HSCs) activation and apoptosis due to DMN treatment. The most evident immunological effect associated with ALOE supplementation was the reduced prevalence of splenic NKT cells ($p=0.02$). In addition, the treatment appeared to increase the total proportion of CD4+ cells among splenic T cells ($p=0.03$) and the interferon- γ production by hepatic Th1 cells ($p=0.06$) tended to increase. In DMN-treated rats, the ALOE supplementation reduced the hepatic hydroxyproline content and α -SMA expression and improved the histopathology compared to controls. These results indicate that ALOE administration may have immunomodulatory effects and lower the fibrogenic process in the liver. *Eur. J. Oncol.*, 14 (2), 93-101, 2009

Key words: *Aloe arborescens*, liver, anti-inflammatory effects, antidiabetic effects, antitumorigenic effects

Introduction

Aloe arborescens Mill var. *natalensis* Berger (so called as "ALOE") belongs to the family of Liliaceae. It is grown in warm tropical areas and cannot survive freezing temperatures. It is a highly valued all-purpose herbal plant traditionally used in the treatment of gastrointestinal complaints, skin injuries and burns.

Aloe arborescens species extracts are rich in pharmacologically active ingredients. It is the type of ALOE which provides 70% of active ingredients, while ALOE VERA provides 40% of active ingredients. Many kinds of ALOE (300-400 classified varieties) are shown. About 20 of them represent varieties of *Arborescens*. *Aloe arborescens* is the most widely diffused species in Brazil and is forwarded to all over the world (1).

In the United States, most of the ALOE is grown in the Rio Grande Valley of South Texas, Florida and Southern California. ALOE can also be found in Mexico, in the Pacific Rim countries, India, South

ziale anti-fibrogenico dell'ALOE è stato valutato sulla base dell'attivazione e dell'apoptosi delle cellule stellate epatiche (CSE), dovuto al trattamento con DMN. L'effetto immunologico più rilevante associato con la supplementazione di ALOE è stata la ridotta prevalenza di cellule NKT spleniche ($p=0,02$). Inoltre, il trattamento sembra aumentare la quota proporzionale di cellule CD4+ tra le cellule T spleniche ($p=0,03$) e la produzione di interferone- γ da parte delle cellule Th1 epatiche ($p=0,06$), che tende ad aumentare. Nei ratti trattati con DMN, la supplementazione di ALOE ha ridotto il tenore in idrossiprolina epatica e l'espressione di α -SMA e si sono rilevati miglioramenti nei reperti istopatologici rispetto ai controlli. Questi risultati indicano che l'utilizzo di ALOE può avere effetti immunomodulanti e attenuare il processo fibrogenico nel fegato. *Eur. J. Oncol.*, 14 (2), 93-101, 2009

Parole chiave: *Aloe arborescens*, fegato, effetti antiinfiammatori, effetti antidiabetici, effetti antitumorali

America, Central America, in the Caribbean, Australia and Africa (2).

The original commercial use of the ALOE plant was in the production of a latex substance called Aloin, a yellow sap. This product became synonymous with the name "ALOE" and recorded in the trade, technical and government literature during the early 20th century. ALOE gel, a clear colorless semi-solid gel, was stabilized and marketed. It is used as a base for nutritional drinks, as a moisturizer, and a healing agent in cosmetics.

The chemical analysis has revealed that this clear gel contains amino acids, minerals, vitamins, enzymes, proteins, polysaccharides and biological stimulators. The public interest in ALOE has quickly grown, and now a considerable amount of researches about the various components of ALOE are carried out in order to find out more about their properties and to characterize these components so that more specific studies can provide clues to the "magic" that is attributed to ALOE. This "magic" concept brought the industry under the Federal Food

and Drug Administration observation in the late 70's and early 80's. The claims made to the consumer about uses and effectiveness of ALOE was exaggerated (2).

Actually, the ALOE industry has established high ethical standards for businesses and their ALOE products. Through the International Aloe Science Council (IASC), the industry has improved its strengths in order to provide the world with the highest quality of ALOE. The wide acceptance of ALOE by society in so many consumer products suggests that the IASC is moving in the proper direction. The IASC has a dedicated group of professionals committed to the further growth, research and marketing of quality ALOE gel and ALOE products made from this gel (2).

Aloe arborescens is one of the approximately 130 ALOE species native to southern Africa. It was one of the first South African ALOES collected and planted in the Company's Garden in Cape Town. The leaves of this plant were used, dried and pounded into a powder, as a protection against storms. Decoctions of the leaves are also used in childbirth and in treating sick calves. In the Transkei, it is used for stomach ache and given to chickens to prevent them from getting sick. In the Orient, this ALOE is grown in domestic gardens as a convenient first-aid treatment for burn wounds and abrasions. In fact it was only after it was used to treat irradiation burn victims of Hiroshima that its healing properties received attention from the West.

The different pharmacological and therapeutic activities of ALOE have been studied: extracts from its leaves have been widely investigated and have shown significant wound healing, anti-bacterial, anti-ulcer, anti-inflammatory (3), anti-carcinogenic (4, 5), hypoglycaemic and also alopoic activity (6). The leaves have also been found to have purgative properties and the leaf sap is reported to relieve x-ray burns (7, 8). In F344 rats, antitumorigenic effects of ALOE have been reported in colorectal tumorigenesis (5) and liver preneoplastic lesions (4).

Zago in 2002 (1) claimed through his personal experience that the ALOE preparation has given positive results in several diseases including cancer (skin, bladder, prostate, liver and others) and degenerative diseases (AIDS, Parkinsonism, Alzheimer, sclerosis, dystrophies and others).

Based on other personal experiences, ALOE preparation (*Aloe arborescens*, honey of bees and distillate) was used by several people who suffered from 2 types of cancer (melanoma and bladder cancer). This procedure was used with great success showing that it is simple, easily available and inexpensive with no contraindications or negative side effects: 3 tablespoonfuls of ALOE per day before meals are administered. Even if ALOE does not guarantee a total healing, it improves the quality of life, probably through strengthening the immune system. If some people have been benefited using this method, why we should not try to prove its effect using available scientific tools? This will offer more opportunity to a great number of sick people.

As confirmed by the above mentioned personal experiences, Pittman (2) discussed the immune enhancing effects of whole ALOE leaf. He indicated that Galactomannans are a class of long chain sugars derived from plants, which have been shown in laboratory and clinical studies to have a wide variety of immune stimulating and protective effects for the body.

In order to further evaluate the beneficial health effects and with the effort to understand the mechanisms behind such effect we carried out two independent but complementary studies. These studies aimed at evaluating the effects of daily supplementation of *Aloe arborescens*, bees' honey and distillate preparation in experimental animals models on the cellular immune functions in the liver of C57BL/6J mice and the anti-fibrogenic potential of ALOE in relationship with hepatic stellate cells (HSCs) activation and apoptosis in dimethylnitrosamine (DMN)-induced fibrotic liver in rats.

Materials and methods

The experimental protocol was approved by the Board of Animal Experiments of the State Provincial Office of Southern Finland. The ALOE mixture included *Aloe arborescens* leaves, honey of bees and distillate traditionally prepared as described by Spiros and Zago (1).

Honey is used in the blend due to its reputations from ancient times as an excellent, genuine food with many beneficial qualities. It is the vehicle

carrying the ALOE and is traditionally thought to clean and remove the impurities it encounters in the gastrointestinal tract. The distillate is also included since it is thought to facilitate the absorption of the ALOE and honey.

The specific protocol for each study is described as follow.

Effect of ALOE preparation on the cellular immune functions in the liver

The studied parameters included the presence and cytokine production of different T-cell populations including different T-cell helper (CD4+) subpopulations (Th1, Th2, Th17 and Tregs), effector T-cells (CD8+), Natural Killer T (NKT) cells and Natural Killer (NK) cells.

Male C57BL/6J mice were housed in an air-conditioned room at 25°C with a 12 hrs dark/light cycle and received human care during the study with unlimited access to chow and water. Initially, mice were randomized into ALOE-treated and control group.

The treated mice were given intragastrically thoroughly homogenised *Aloe arborescens* preparation 0.1 ml per day by oral feeding needle for 21 days while four control mice received the same amount of sterile 0.9% NaCl. Mice were given free access to feed and water. The mice were sacrificed on day 22 by CO₂ overdose. The hepatic portal vein was cannulated with 25G needle and the liver perfused with 5 ml of ice cold PBS after which the liver was surgically removed and placed on Petri dish with media. All media were kept ice cold throughout the cell isolation procedures.

For the isolation of splenocytes the spleen was homogenized in media and the suspension was then transferred to 50 ml conical tube through a 70 µm pore size cell strainer. Cells were collected by centrifugation 5 min/200-300 g/4°C and red blood cells removed by incubating twice in Red Blood Cell Lysing Buffer (Sigma R7757) and washing with media according to the manufacturer's instructions. The erythrocyte-depleted cells were resuspended in media and stored on ice at 4°C o/n until stimulation and staining for flow cytometer experiments.

The liver was cut into segments in order to isolate the hepatocytes. The segments were pressed through

70 µm pore size cell strainer (BD Bioscience) into media in a 50 ml conical tube using the flat end of a 5 ml syringe plunger and washing with media. Cell suspension was centrifuged twice at 30 g for 3 min at 4°C to remove dense parenchymal cells. The rest of the cells were harvested from the supernatant by centrifugation at 300 g, 4°C for 10 min. The hepatic mononuclear cells were isolated from the pellet through flotation density gradient centrifugation. For this purpose the pellet was resuspended in a mixture of RPMI-1640 and OptiPrep™ (Axis Shield) media in a ratio giving $\rho=1.122$. This suspension was overlaid with Hank's balanced salt solution ($p<1.006$, Sigma) after which the tubes were centrifuged for 20 min at 1500 g, 4°C. Hepatic mononuclear cells were harvested from the interface, resuspended in media and stored on ice at 4°C o/n until stimulation and staining for flow cytometer experiments.

Aliquots of isolated cells were used without further stimulation for staining regulatory T cells (Tregs). For the intracellular cytokine assays the cells were first incubated in concentration of 2×10^6 cells/ml with 10 µg/ml of Brefeldin A (inhibiting secretion of cytokines outside the cell) as well as with or without polyclonal stimuli 25 ng/µl of phorbol myristate acetate (PMA) and 1 µg/ml of ionomycin for 5 hours at 37°C with 5% CO₂. Cells were harvested through centrifugation at 300 g, 4°C for 7 min.

Regulatory T-cells were stained using Mouse Regulatory T cell Staining Kit #2 (eBioscience) with antibodies FITC anti-mouse CD4 (RM4-5), PE anti-mouse CD25 (PC61.5) and APC anti-mouse/rat Foxp3 (FJK-16s) according to the manufacturer's instructions. APC Rat IgG2a was used as an isotype control.

The surface and intracellular staining of Th1 (CD3+CD4+IFN-gamma+IL-4-), Th2 (CD3+CD4+IL-4+IFN-gamma-), Th17 (CD3+CD4+IL-17+IFN-gamma-), NK (CD3-nk1.1+) and plausible NKT (CD3+nk1.1+) cells was performed in 12 x 75-mm polystyrene flow cytometer tubes (BD Bioscience) using FIX&PERM cell permeabilization kit (Caltag/Invitrogen) according to the manufacturer's instructions. Before surface receptor staining the cells were incubated with Mouse BD Fc Block (BD Bioscience) in order to minimize background staining. Antibodies used included APC-Cy7 anti-mouse CD4 (RM4-5), PE-Cy7 CD8 (<http://www.>

biosite.se/ViewProduct.aspx?id=74128 53-6.7), PE IL-4 (11B11), Alexa 488 IFN- γ (XMG1.2) and Alexa647 IL-17 (<http://www.biosite.se/ViewProduct.aspx?id=79690> TC11-18H10.1) from BioLegend (Nordic Biosite) and PerCP-Cy5.5 NK-1.1 (NKR-P1B and NKR-P1C) from BD Bioscience.

The cells were immediately analyzed after staining with BD FACSCanto™ II Flow Cytometry System (BD Biosciences) and using BD FACS-Diva™ 6.0 software. Statistical analyses were performed using SPSS 16.0 for Windows.

Effect of ALOE preparation on liver fibrosis

Fourty male Wister rats (180~200g) were housed in an air-conditioned room at 25°C with a 12 hrs dark/light cycle and received human care during the study with unlimited access to chow and water. Initially, rats were randomized into 2 groups: control group (n=10), dimethylnitrosamine-treated group (DMN; n=30). DMN (10 mg/kg bwt) was intraperitoneally administered to the DMN-treated group rats for 3 consecutive days each week, control rats received the same amount of physiological saline solution (9).

At the end of the second week, 3 and 6 rats from the control and DMN-treated group were sacrificed in order to assess the fibrosis development, respectively. The remaining DMN rats were further randomized into 2 groups, DMN-water group (n=12) and DMN-ALOE VERA group (n=12). Both groups continued to receive the weekly treatment with DMN for further 2 weeks and in addition to a daily administration of either water or ALOE VERA which was intragastrically given. The ALOE VERA was given at a dose of 0.418 g/100 g bwt which is equivalent to human dose in clinical therapeutics; water was also administered at the same dose as ALOE VERA. At the end of the fourth week, all animals were sacrificed, the liver was excised and samples were taken out for the following investigations.

Histological analysis

Liver specimens were preserved in 4% paraformaldehyde and dehydrated in a graded alcohol series. Specimens were then embedded in paraffin blocks, cut into 5 μ m-thick sections and

placed on glass slides. Sections were then stained with Sirius Red.

Hydroxyproline determination

Hepatic hydroxyproline content was used such as an indirect measure of the tissue collagen content. Hydroxyproline from liver tissue (100 mg) was determined according to Jamall's method (10). Hydroxyproline content was expressed as μ g per g of liver wet weight.

Immunohistochemistry

After deparaffinization and dehydration, microwave antigen retrieval was performed for 5 min before the peroxidase quenching with 3% H₂O₂ in PBS for 15 min. The sections were then preblocked with 5% bovine serum albumin for 30 min. Slides were incubated at 4°C with anti- α -SMA antibody (Sigma, A2547, 1:400, USA) overnight, then with biotinylated secondary antibodies for 45 min. After that, they were developed with diaminobenzidine (DAB) for 3 min and finally counterstained with hematoxylin.

Results and Discussion

Effect of ALOE on the cellular immune functions

ALOE administration appeared to have some systemic immunomodulatory effects. The most notable effect was observed in the presence of splenic NKT-cells (CD3+NK1.1+), which was markedly reduced in comparison with controls (fig. 1) (p=0.02). The effect was comparable in CD4+ and CD4-T cells expressing the NK and NKT cell marker NK1.1 antigen but not significant in CD8+ NK1.1 expressing T cells (data not shown). Also the proportion of NKT cells producing IFN- γ but not those producing IL-4 was significantly reduced among splenic lymphocytes (p=0.04, data not shown) NKT cells formed the heterogenic relatively poorly understood cell population of the innate immune system. They received increasing attention due to their regulatory rôle in host immunity against variety of microbes and tumours and pathogenesis of autoim-

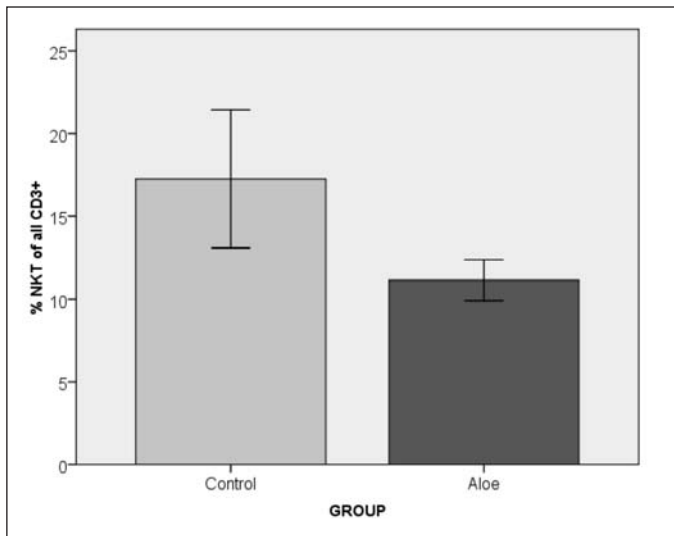


Fig. 1. The effect of ALOE on splenic NKT cells. The percentage of plausible NKT cells (CD3+NK1.1+) of all T cells (CD3+) was significantly higher in control than ALOE-treated mice ($p=0.02$).

mune diseases and asthma. However, whether they show beneficial or negative influence, it appeared to vary in different conditions and depending on the NKT subtype (11-14). In contrast to its effects on NKT cells, ALOE seemed to increase the proportion of all T cells helper (CD4+) among all splenic T-cells (CD3+) with a mean percentage of 55% (95% CI 52 to 58) as compared to 50% (45 to 55) in controls ($p=0.03$). These findings are particularly interesting considering the frequent use of ALOE in skin care products suggesting that NKT cells appear to suppress immune responses against ultraviolet induced skin cancers.

In the liver, oral supplementation of ALOE appeared to modestly increase the production of IFN- γ by Th1 cells which could be effective in the clearance of liver infections and tumours due to the rôle of Th1 cells in mediating the formation of high

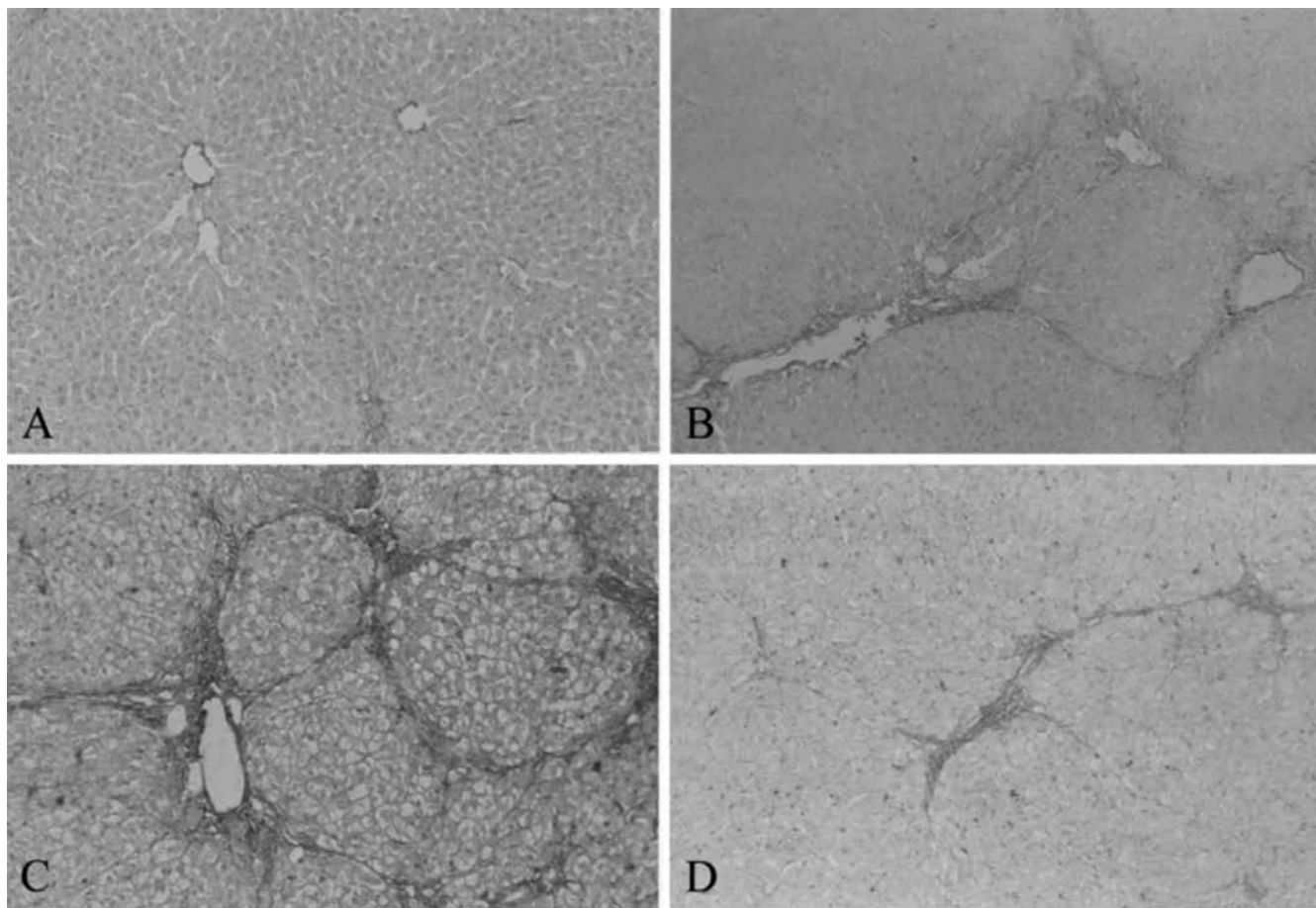


Fig. 2. Effects of ALOE on histological changes. (Sirius Red staining X100) of rat livers. DMN (10 mg/kg) was intraperitoneally administered to DMN-treated rats for 3 consecutive days each week for 4 weeks; control rats received equal physiological saline. At the 2nd weekend, 6 DMN-treated rats were sacrificed for observation; the remaining rats were submitted to 4 weeks DMN rats given water (DMN+ water) or ALOE (DMN+ ALOE). Liver sections were obtained from control rats (A), 2 weeks DMN (B), 4 weeks DMN +water (C), and DMN+ ALOE (D).

anti-viral and anti-tumour responses (fig. 2). The ALOE supplementation did not have significant effect on any other studied immunological parameters. The potential for type II error due to small sample number cannot be fully ruled out.

Effect of ALOE on liver collagen deposition

In control rats, Sirius Red staining was observed in centrolobular vein wall and portal connective tissue; following DMN-administration for 2 weeks, fibrotic lesions were classically observed around centrolobular veins and in thin septa between centrolobular zones. In DMN-water group, a severe fibrosis and worsened distortion of hepatic architecture was observed. Furthermore, a fibrosis expansion of the portal tracts with marked portal-to-portal and portal-to-central bridging and cirrhotic nodule formation, and developed pseudolobules were also observed. However, in DMN-ALOE group, liver fibrosis markedly decreased with reduced thickening of these collagen bundles in comparison with the DMN-water group (fig. 2).

Effect of ALOE on hepatic hydroxyproline content

The alteration of hepatic hydroxyproline levels is considered as an index of collagen metabolism and provides valuable information about the biochemical and pathologic events of hepatic fibrosis. The DMN treatment was approximately 161% of that in the control group ($p < 0.01$) suggesting abundant accumulation of collagen in DMN-treated rats. Hydroxyproline content was significantly increased to 360% ($p < 0.01$) in DMN-water rats compared to controls: such an increase coincided with the observation of marked cirrhosis and accumulation of collagen bundles in the liver through histopathological examination. On the contrary, a 41% reduction in hydroxyproline content ($p < 0.05$) in DMN-ALOE group in comparison with DMN-water group, suggested that ALOE ameliorated hepatic collagen deposition in DMN-induced liver injury (fig. 3).

Effect of ALOE on α -SMA immunohistochemistry, mRNA and protein expression

Using an antibody against α -SMA, a marker of stellate cell activation, we immunohistochemically

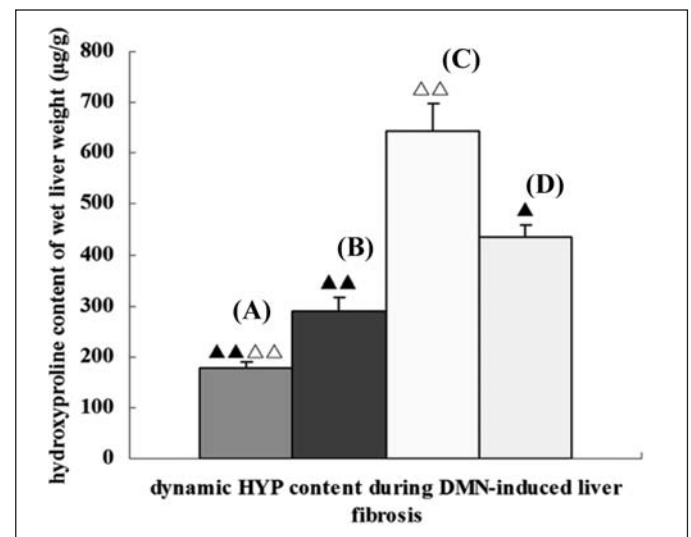


Fig. 3. Effects of ALOE on hydroxyproline (HYP) content of rat livers.

DMN (10 mg/kg) was intraperitoneally administered to DMN-treated rats for 3 consecutive days each week for 4 weeks; control rats received equal physiological saline. At the 2nd weekend, 6 DMN-treated rats were sacrificed for observation; the remaining rats were submitted to 4 weeks DMN rats given water (DMN+water) or ALOE (DMN+ALOE). Liver sections were obtained from control rats (A), 2 weeks DMN (B), 4 weeks DMN +water (C), and DMN+ALOE (D). ▲ $p < 0.05$, ▲▲ $p < 0.01$, vs. DMN+water rats; ▲ $p < 0.05$, ▲▲ $p < 0.01$ vs. 2 weeks DMN rats. Results are mean \pm SD.

assayed the expression of this protein. In control rats, vascular smooth muscle cells were strongly positive for α -SMA, whereas HSCs positive for α -SMA were rarely observed. Following DMN-treatment, many α -SMA-positive HSCs were detected in areas of centrolobular and periportal fibrotic bands, the number of α -SMA-positive HSCs gradually increased and reached peak at 4 weeks in cirrhotic liver. However, a marked reduction in numbers of α -SMA-positive HSCs was observed in DMN-ALOE compared to DMN-water group (fig. 4).

Conclusion

In conclusion, the data herein presented demonstrated that *Aloe arborescens* preparation may have systemic immunomodulatory effects: its physiological significance remains to be assessed. Moreover, the study suggested that ALOE shows fibrosuppressive effects against liver fibrosis in DMN-induced

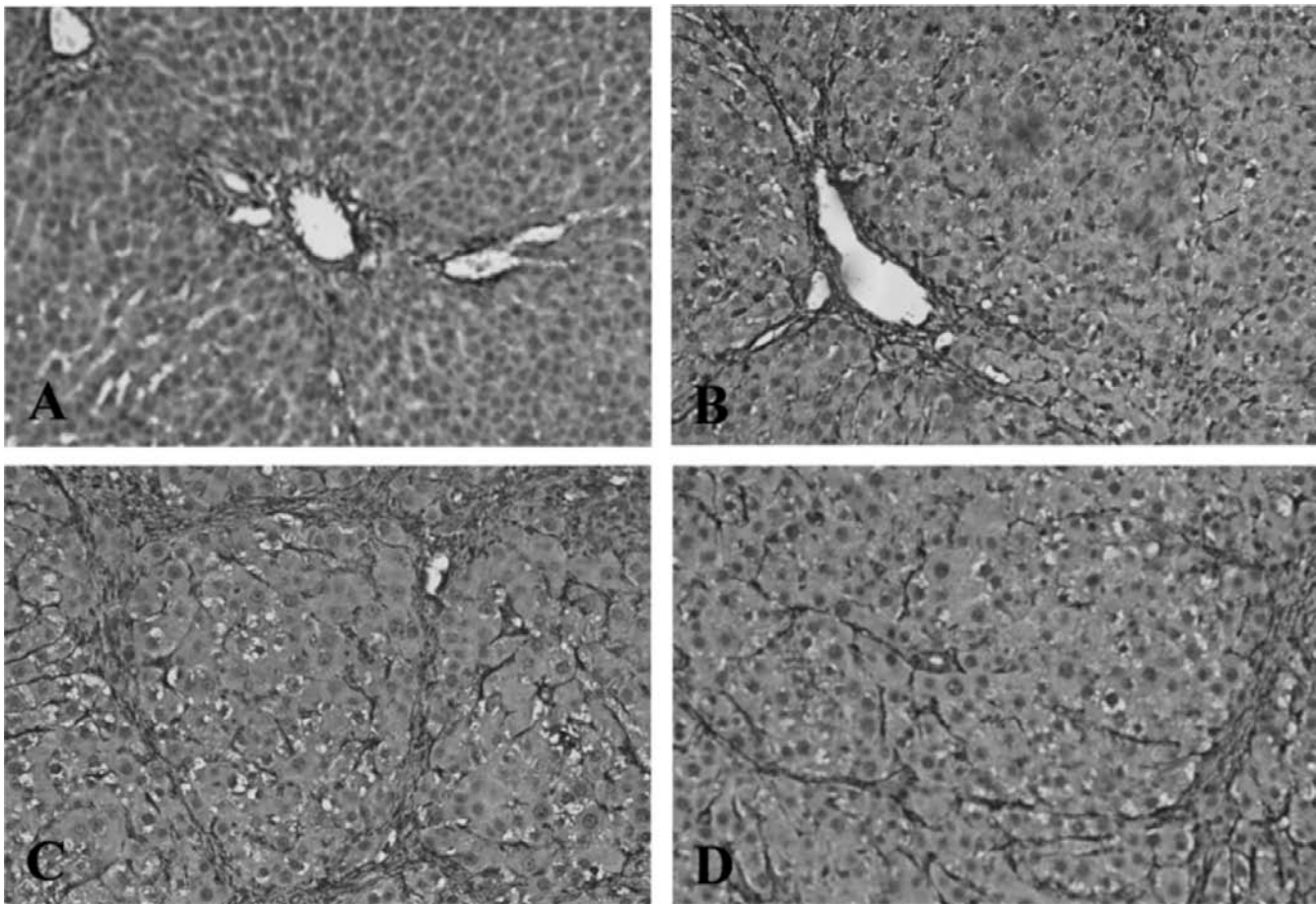


Fig. 4. Immunohistochemical analysis of α -SMA in DMN-treated rats. DMN (10 mg/kg) was intraperitoneally administered to DMN-treated rats for 3 consecutive days each week for 4 weeks; control rats received equal physiological saline. At the 2nd weekend, 6 DMN-treated rats were sacrificed for observation; the remaining rats were submitted to 4 weeks DMN rats given water (DMN+water) or ALOE (DMN+ALOE). In control rats, vascular smooth muscle cells were strongly positive for α -SMA, whereas HSCs positive for α -SMA were rarely observed (A). Following DMN-treatment, many α -SMA-positive HSCs were detected in areas of centrolobular and periportal fibrotic bands (B), the number of α -SMA-positive HSCs gradually increased and reached peak at 4 weeks (C) in cirrhotic liver. However, a marked reduction in numbers of α -SMA-positive HSCs was observed in DMN-ALOE (D) (X200). Liver sections were obtained from control rats (A), 2 weeks DMN (B), DMN+water (C), DMN+ALOE (D).

rats. It ameliorated hepatic collagen deposition in DMN-induced liver injury. Hepatic hydroxyproline content was decreased with improved histopathology in ALOE-treated rats. This effect may be caused at least in part by its inhibitory action against HSCs activation to reduce ECM protein expression. However, which components in *Aloe arborescens* played an effective rôle in DMN-induced liver fibrosis need further researches.

Acknowledge

This study was funded by Spiros Foundation (Project number 69098, University of Kuopio, Finland).

References

1. Padre Romano Zago, OFM. ADLE Ed. Padova, 2002.
2. The International Aloe Science Council, Copyright 1996-2002. Available at <http://www.iasc.org/aloe.html>
3. Fujita K, Yamada Y, Azuma K, *et al.* Effect of leaf extracts of *Aloe arborescens* Mill subsp. *natalensis* Berger on growth of *Trichophyton mentagrophytes*. Antimicrob Agents Chemother 1978; 14: 132-6.
4. Tsuda H, Matsumoto K, Ogino H, *et al.* Demonstration of initiation potential of carcinogens by induction of preneoplastic glutathione S-transferase P-form-positive liver cell foci: possible in vivo assay system for environmental carcinogens. Jpn J Cancer Res 1993; 84: 230-6.
5. Shimpo K, Beppu H, Chihara T, *et al.* Effects of aloe arborescens ingestion on azoxymethane-induced intestinal carcinogenesis and hematological and biochemical para-

- meters of male F344 rats. Asian Pac J Cancer Prev 2006; 7: 585-90.
6. Beppu, H, Shimpo K, Chihara T, *et al.* Antidiabetic effects of dietary administration of *Aloe arborescens* Miller components on multiple low-dose streptozotocin-induced diabetes in mice: investigation on hypoglycemic action and systemic absorption dynamics of aloe components. J Ethnopharmacol 2006; 103: 468-77.
 7. Vvan Wyk BE, Gericke N. People's Plants. Briza Publications, Pretoria, 2000.
 8. Leistner OA. Seed plants of southern Africa: families and genera, Strelitzia 10. National Botanical Institute, Pretoria, 2000 (editorial).
 9. Ala-Kokko L, Pihlajaniemi T, Myers JC, *et al.* Gene expression of type I, III and IV collagens in hepatic fibrosis induced by dimethylnitrosamine in the rat. Biochem J 1987; 244: 75-9.
 10. Jamall IS, Finelli VN, Que SS. A simple method to determine nanogram levels of 4-hydroxyproline in biological tissues. Anal Biochem 1981; 112: 70-5.
 11. Li D, Xu XN. NKT cells in HIV-1 infection. Cell Res 2008; 18 (8): 817-22.
 12. Swain MG. Hepatic NKT cells: friend or foe? Clin Sci 2008; 114 (7): 457-66.
 13. Ambrosino E, Berzofsky JA, Terabe M. Regulation of tumor immunity: the role of NKT cells. Expert Opin Biol Ther 2008; 8 (6): 725-34.
 14. Meyer EH, DeKruyff RH, Umetsu DT. T cells and NKT cells in the pathogenesis of asthma. Ann Rev Med 2008; 59: 281-92.

